

OSAT – Upper Endoscopy OSAT

Preoperative evaluation	Performs a complete history and physical, knows the indications for the procedure	Unsure of the reasons for the procedure	Did not see the patient pre-op
Preoperative consent	Able to explain risks and benefits of the procedure eloquently and answer all questions appropriately	Explains procedure, but not able to answer patient/family's questions	Does not talk to patient pre-op
Preoperative workup	Checks on the lab results and orders any other necessary tests, orders any necessary medications	Knows the lab results were normal	Unaware of results of preoperative lab work/other tests
Upper airway anatomy	Can accurately describe	Has difficulty/needs prompting	Unable to describe
Patient preparation	Proper positioning, oxygen, monitors, sedation, topical anesthetic, bite block	4-5 of these things done	Less than 4 of these things done without prompting
Movements of hands on controls	All movements purposeful	Usually purposeful, some unnecessary movements	Many unnecessary movements
Force used	Gentle at all times, Appropriate but never excessive force.	Gentle usually, excessive force sometimes.	Rough, Dangerous, uses excessive force
Scope handling	Skilled/expert	Confident, competent scope handling appeared awkward occasionally	Looks awkward
Time spent in red-out (Absence of luminal vision)	minimal	25-50% of the time	50-75% of the time
Reaction to red-out (absence of luminal vision)	Waited/withdrew/insufflate all times	Waited/ withdrew/insufflate most times	Advanced without suitable caution
Use of Torque	Always When necessary	Usually when necessary	Never
Ability to transverse pylorus and evaluate duodenal bulb	Always	Usually	Only with great difficulty
Ability to safely navigate 2 nd and 3 rd portions if duodenum	Always	Usually	unable
Patient discomfort	Minimal discomfort for <10% of the procedure	Minimal discomfort for 25-50% of the procedure	Severe discomfort for >25% of the procedure
Reaction to patient discomfort	Appropriate safety measures at all times	Stopped, waited, withdrew (appropriate safety measures) most times	Ignores discomfort, Advanced regardless of patient's discomfort
Flow of procedure	Confident, sure of what to do at all times	Usually confident, hesitated occasionally	Hesitated often, unsure of what to do.
Pathology	Reviewed all 74 photos of esophageal, gastric, and duodenal disease at website listed below.	Can identify common pathology. Did NOT review website.	Unable to appreciate abnormalities
Biopsy indications and technique	Accurately describes and performs	Has difficulty, or wrong location	Unable to perform/unaware
Complications	Can name 5 complications, and how to manage them	Can name a couple complications, unsure about management	Unaware of the complications of the procedure
Follow up	Develops appropriate follow-up plan and communicates this to the patient/family	Unsure how to manage the patient from this point	Does not speak to the patient or write any discharge instructions
Overall performance	Fail	Pass	Proficient

Endoscopy pathology website: <http://www.gastrointestinalatlas.com/English/english.html>

Website reviewed by resident not reviewed

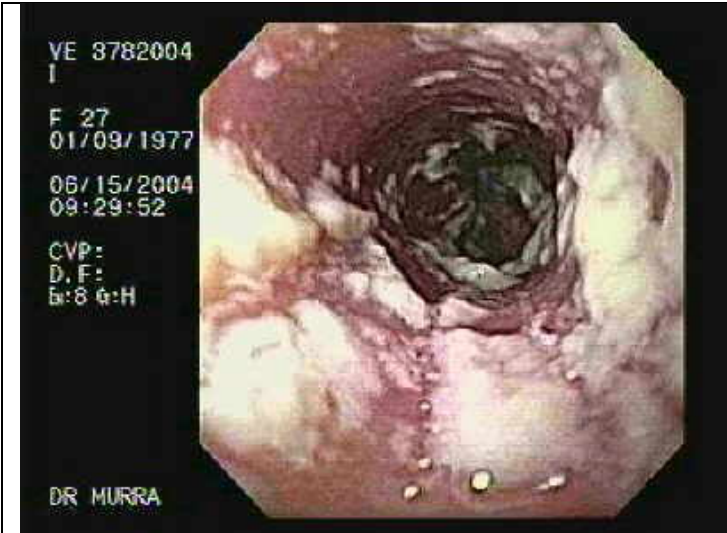
Resident

Attending Surgeon – St. Francis Hospital

date

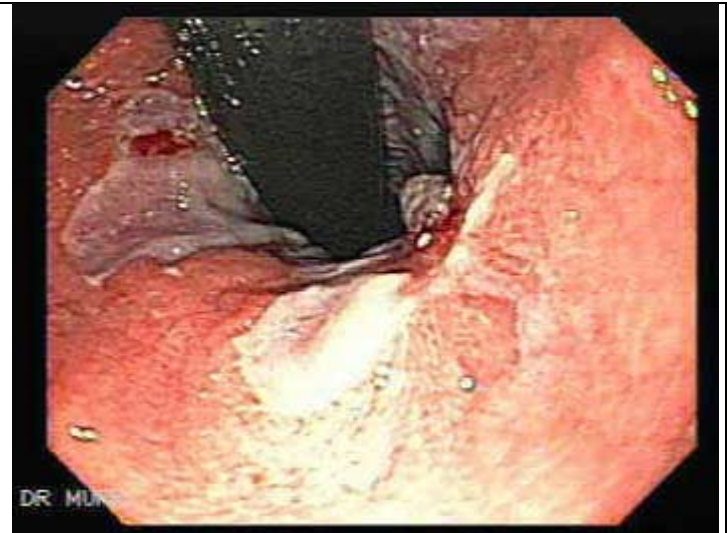


OSAT – Upper Endoscopy OSAT



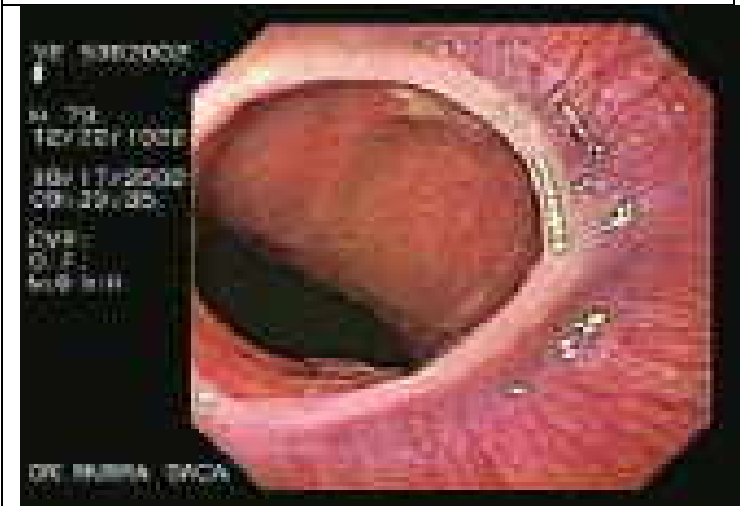Please Identify Above

1:



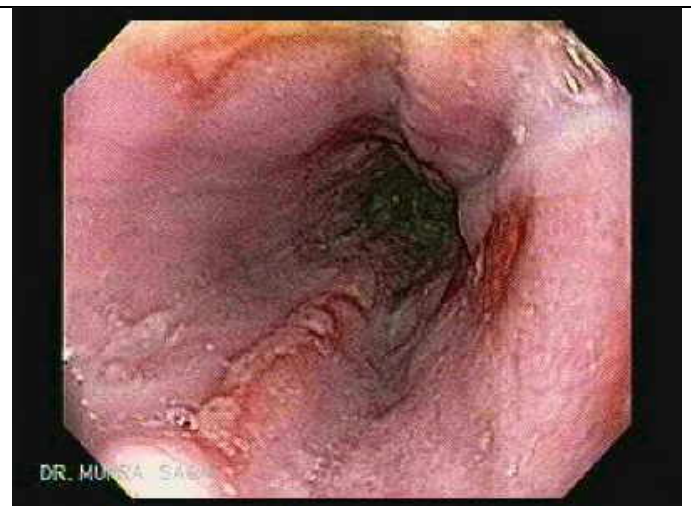
Please Identify Above

4:



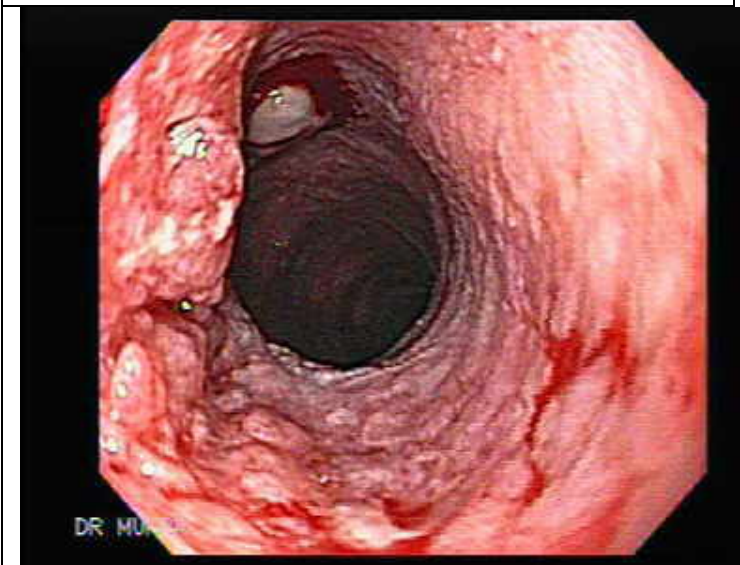
Please Identify Above

2:



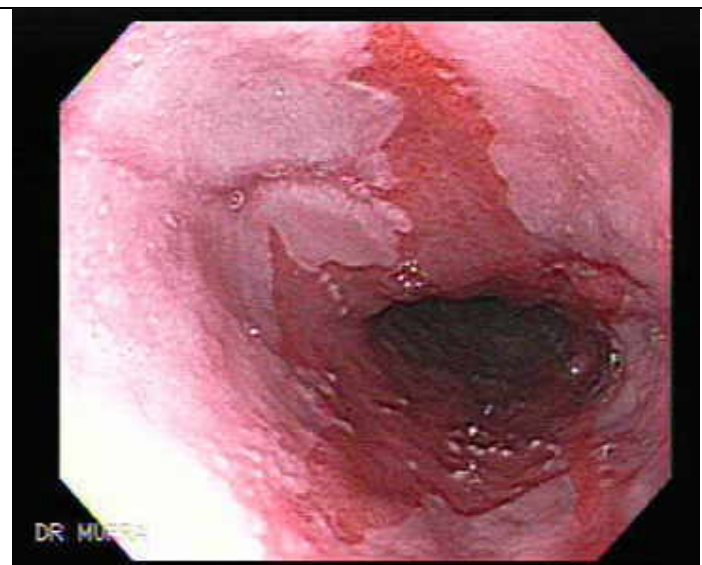
Please Identify Above

5:



Please Identify Above

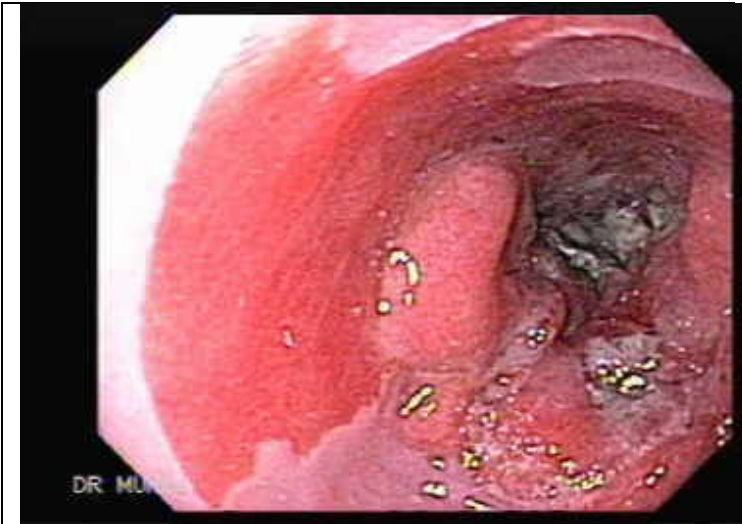
3:



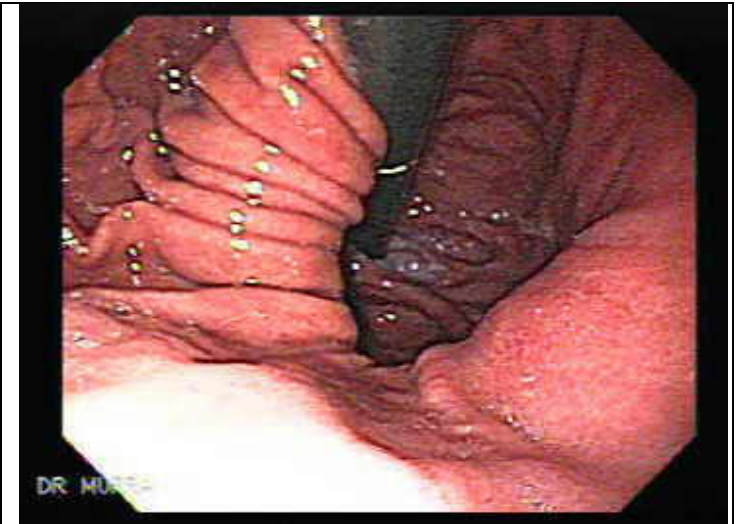Please Identify Above

6:

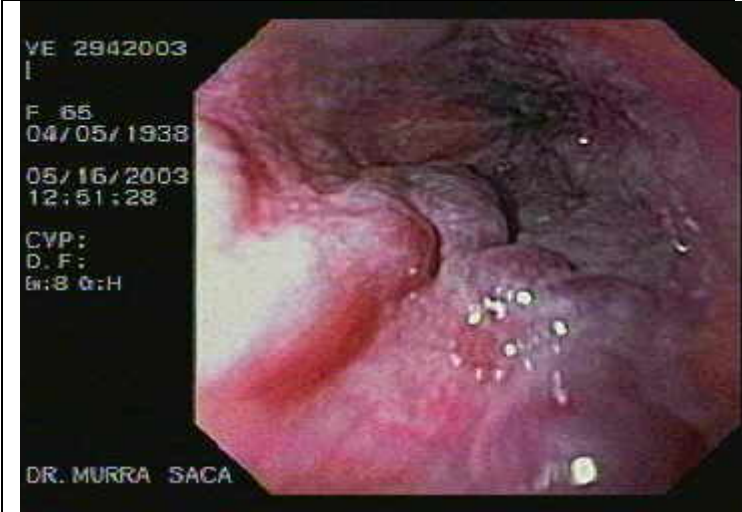
OSAT – Upper Endoscopy OSAT



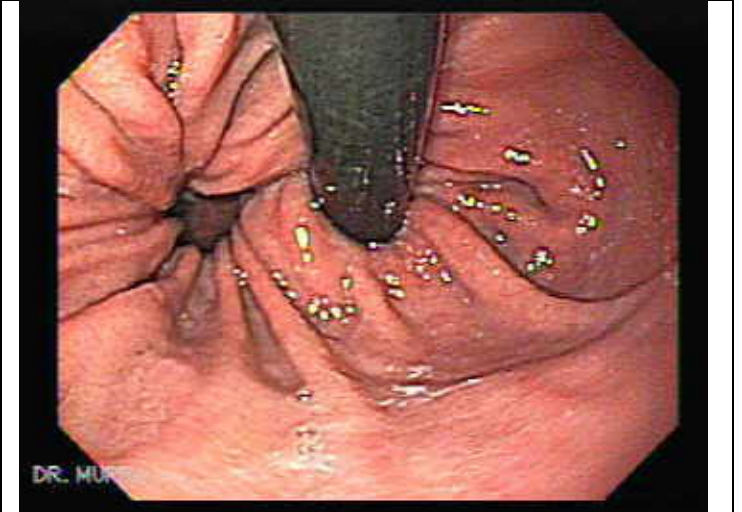Please Identify Above
7:



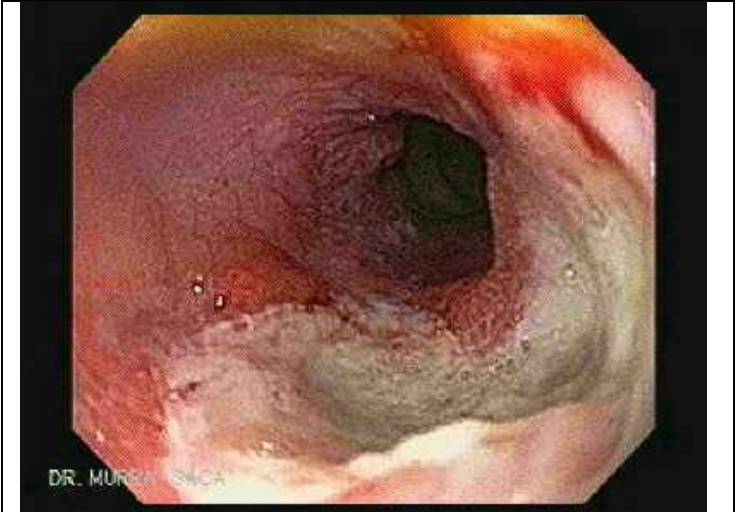
Please Identify Above
10:



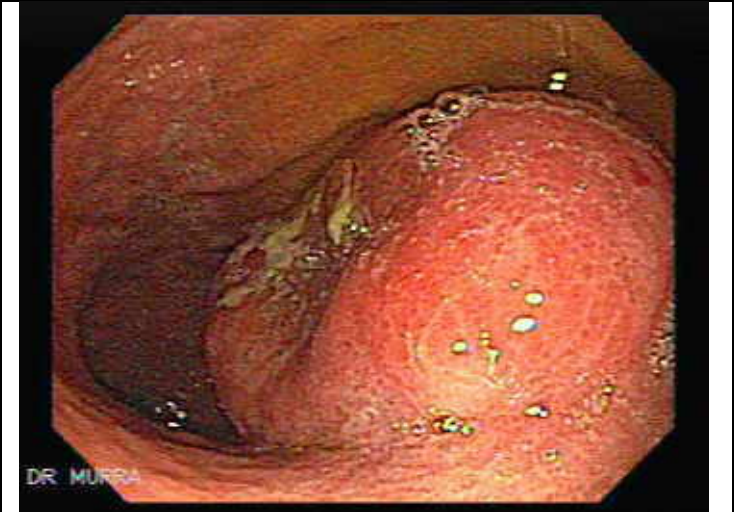Please Identify Above
8:



Please Identify Above
11:

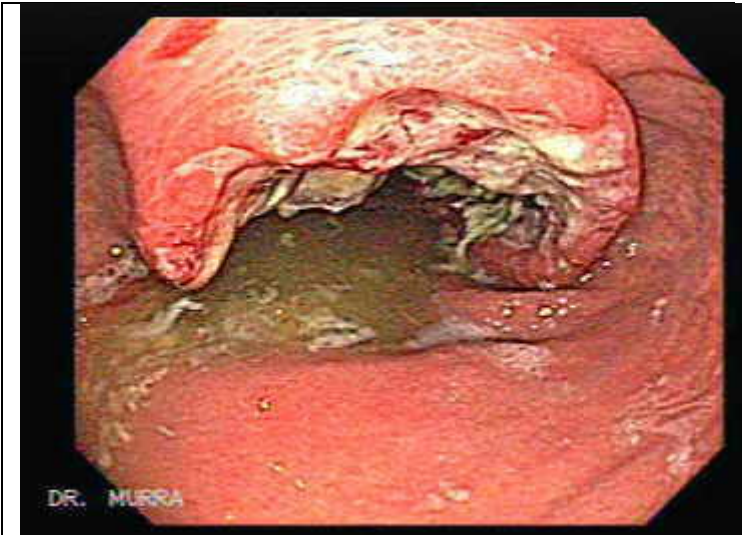


Please Identify Above
9:

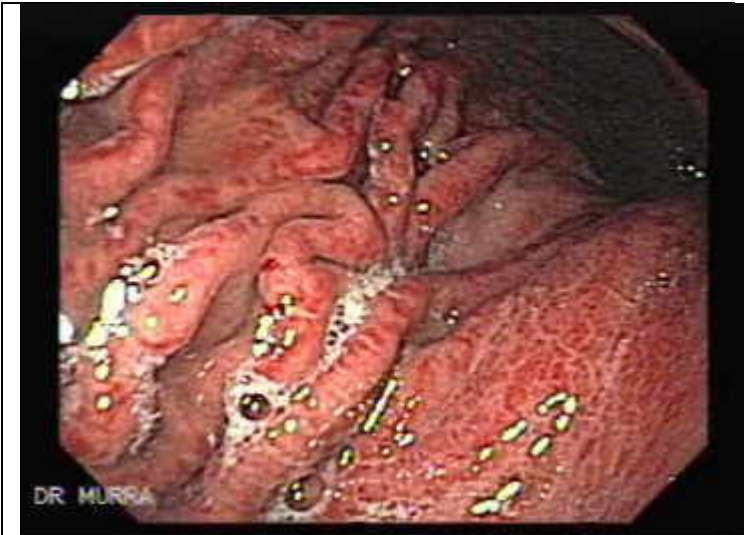

Please Identify Above
12:

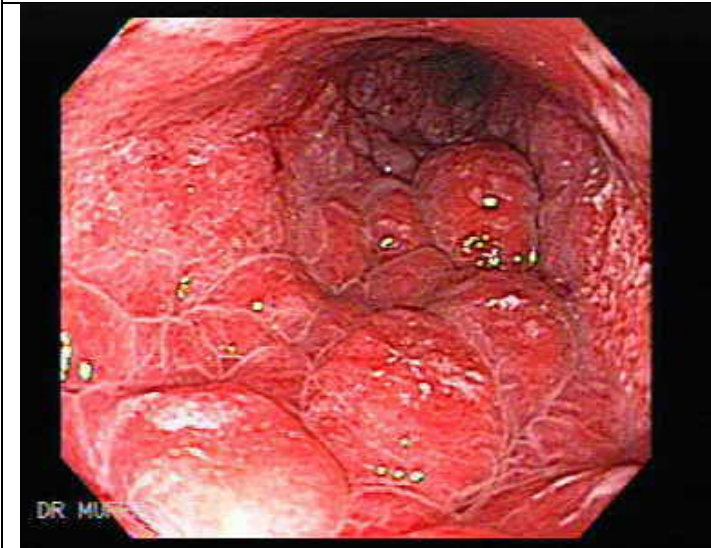
OSAT – Upper Endoscopy OSAT



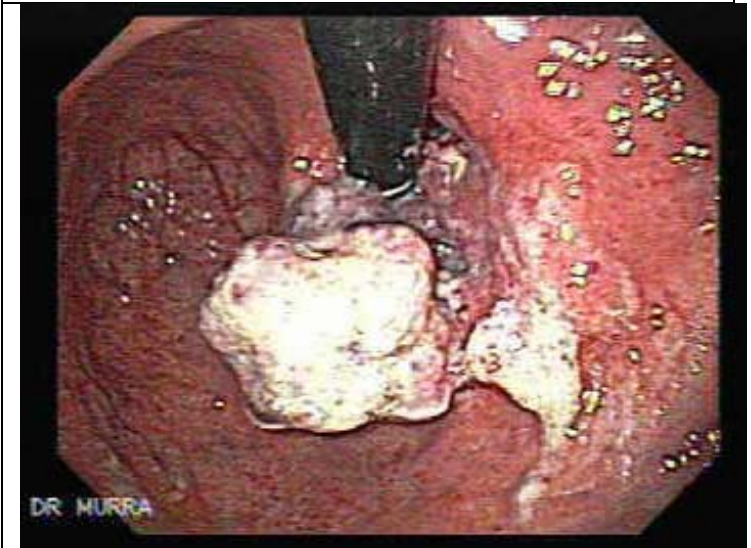
Please Identify Above
13:



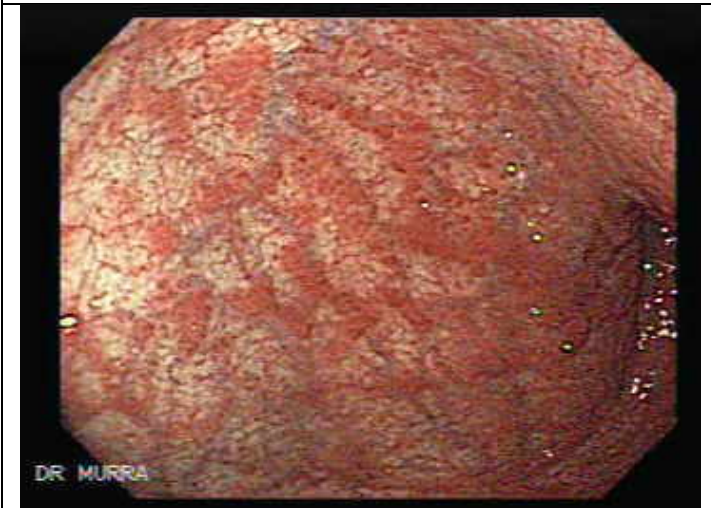Please Identify Above
16:



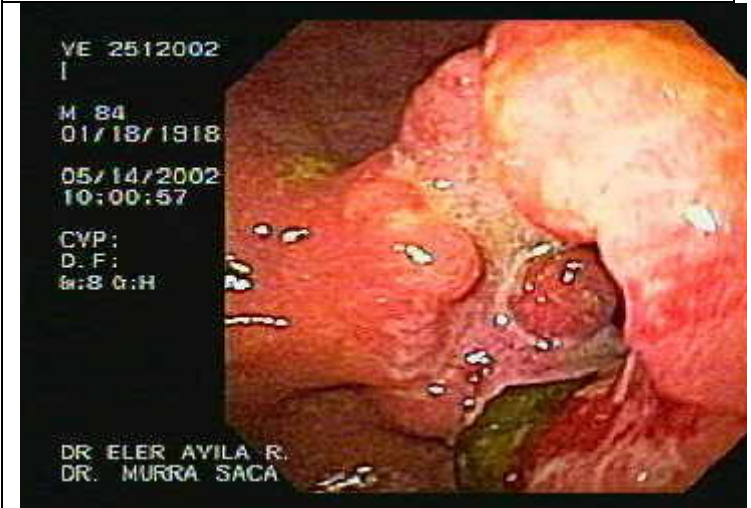
Please Identify Above
14:



Please Identify Above
17:

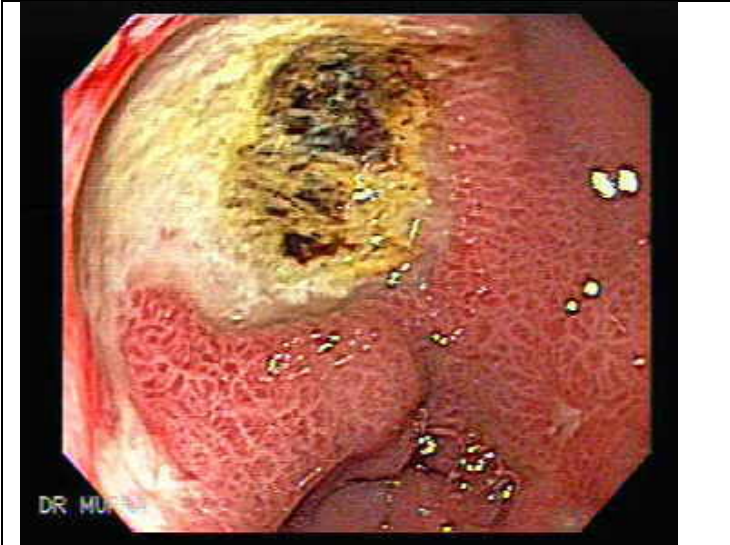


Please Identify Above
15:

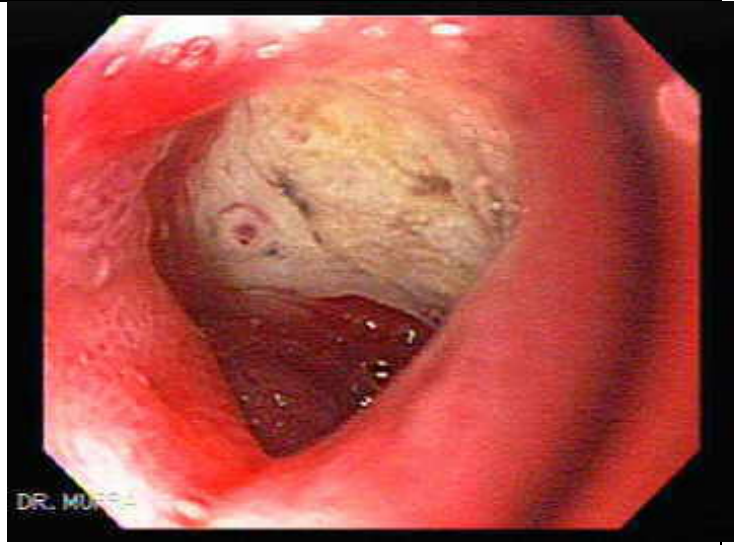


Please Identify Above
18:

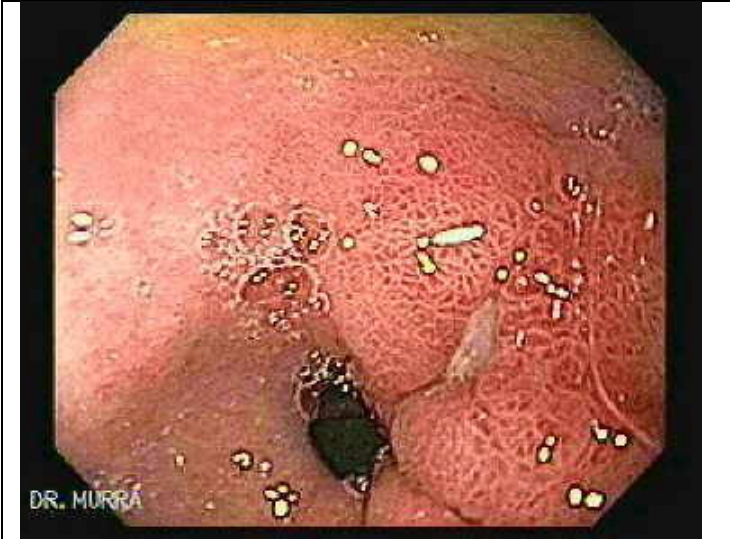
OSAT – Upper Endoscopy OSAT



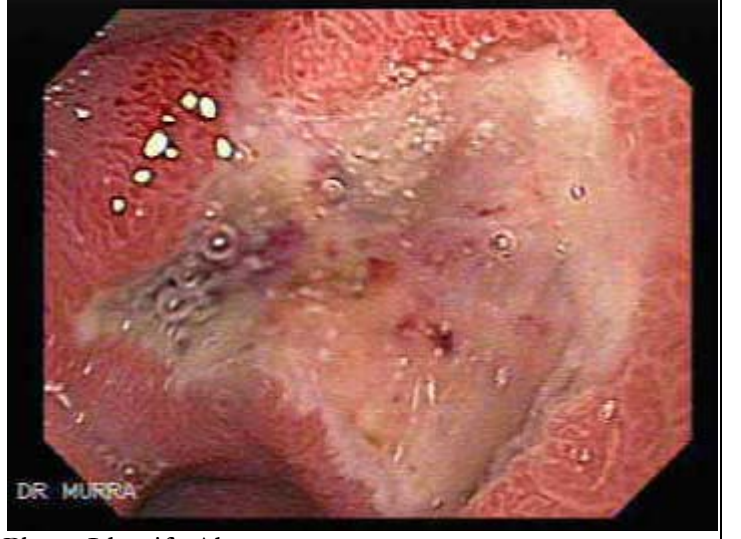Please Identify Above
19:



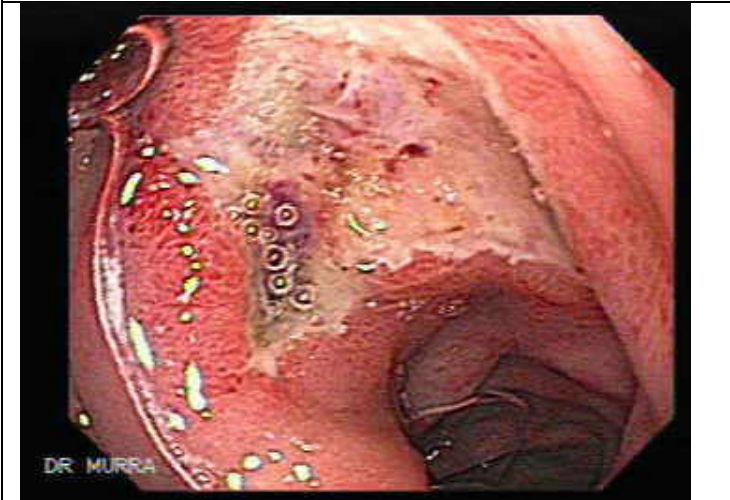
Please Identify Above
22:



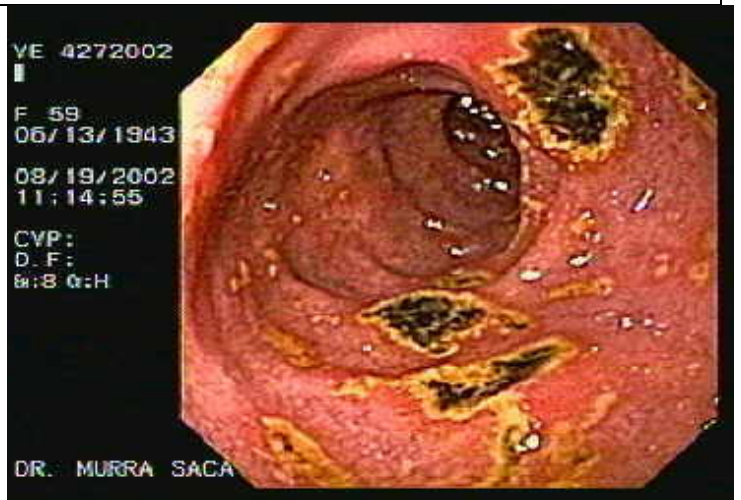
Please Identify Above
20:



Please Identify Above
23:

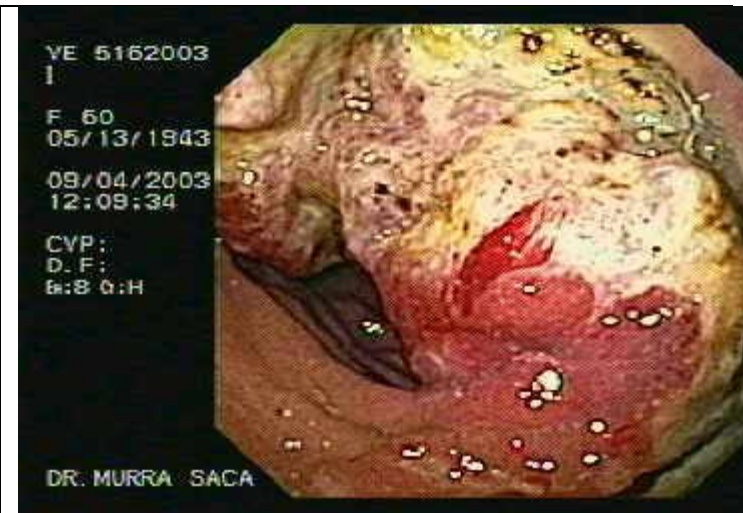


Please Identify Above
21:

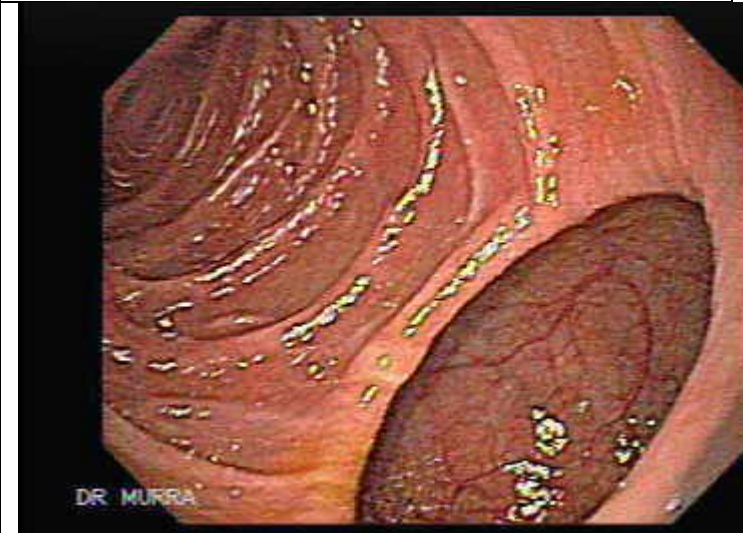

Question 24:

OSAT – Upper Endoscopy OSAT



Please Identify Above
25:



Please Identify Above
26: